
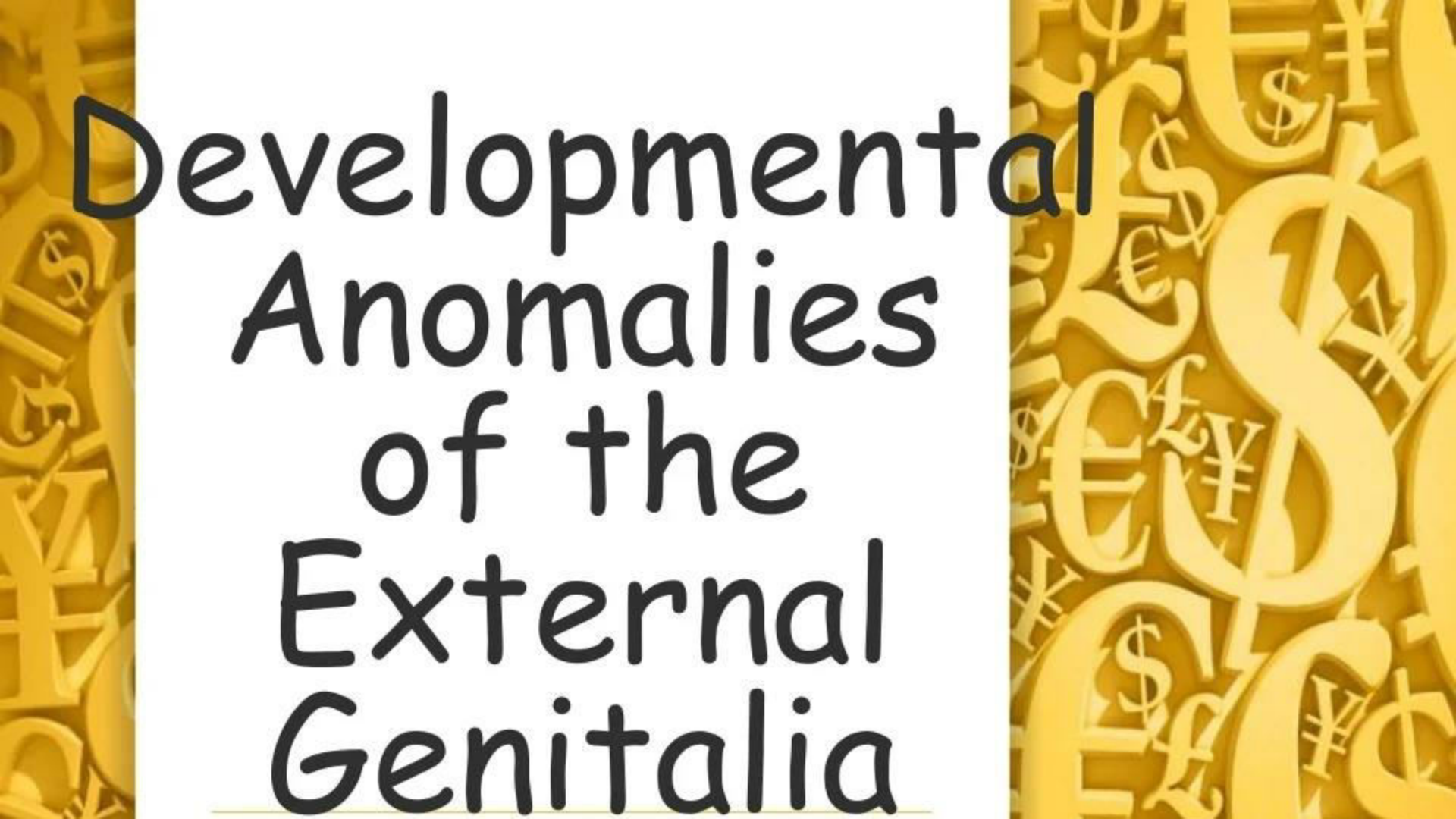


The slide features a decorative border on both the left and right sides. This border consists of a dense, overlapping pattern of various international currency symbols, including the dollar sign (\$), euro (€), yen (¥), and pound sterling (£), rendered in a golden-yellow color. The central area of the slide is white and contains the main title text.

Congenital Malformations of Female Genital Organs

- 
-
- These are genetic in origin...
 - Major anatomic defect of the FGT is usually associated with normal gonadal function and urinary tract abnormality.

Developmental Anomalies of the External Genitalia

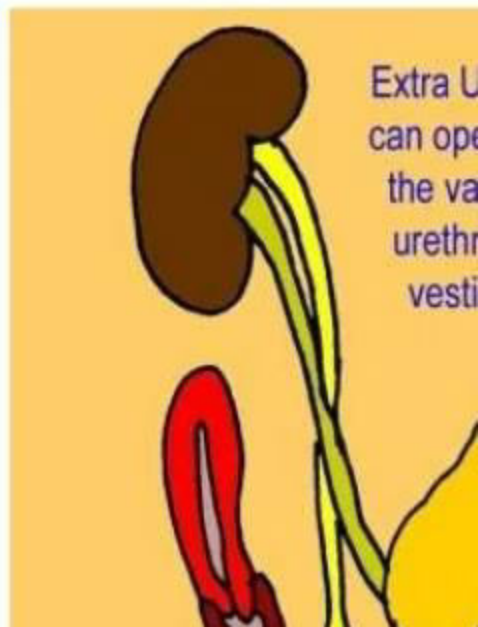


PERINEAL OR VESTIBULAR ANUS

- Detected at the time of birth
- Usual anal opening site is evidenced by anal pit
- Either anus will be situated close to the posterior end of the vestibule or in the vestibule.
- In vagina (rarely) → (congenital rectovaginal fistula)
- Opening is usually sufficiently big

ECTOPIC URETER

- Additional ureteric opening is usually in the vestibule close to the urethra or in the vagina.
- Symptom:-
 - Uncontrollable wetness
- Partial nephrectomy and ureterectomy may be indicated or implantation of the ectopic ureter into



The background of the slide is a light yellow color. On the left and right sides, there are vertical decorative borders. These borders feature a dense, overlapping pattern of various international currency symbols, including the dollar sign (\$), the euro symbol (€), the pound sterling symbol (£), and the yen symbol (¥). The symbols are rendered in a slightly darker shade of yellow, creating a textured, metallic appearance. In the center of the slide, the text "Vaginal Abnormalities" is displayed in a large, bold, black, sans-serif font. Below the text, there is a thin, horizontal yellow line that spans across the width of the text area.

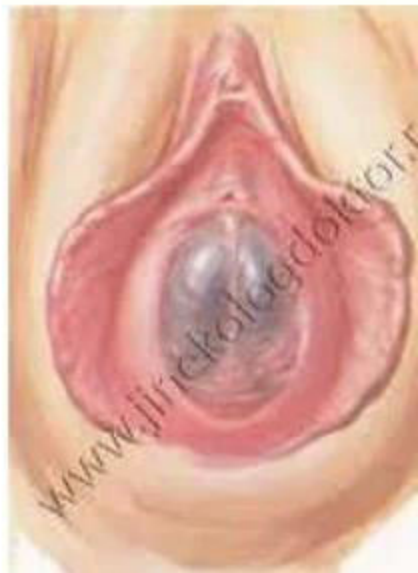
Vaginal Abnormalities

NARROW INTROITUS

- Revealed after marriage..
- **DYSPAREUNIA MAY BE THE FIRST COMPLAINT** or it may be detected during investigation of infertility
- Treatment is effective by manual stretching under general anaesthesia or by surgical enlargement.

HYMEN ABNORMALITY

- Imperforate hymen → of significance abnormality.
 - Always unnoticed until 14 – 16 yrs.
 - Uterine functioning is normal → menstrual blood is pent up inside vagina behind the hymen (**CRYPTOMENORRHOEA**)
 - Depending upon the amount of blood so accumulated, it first distends the vagina (**HAEMATOCOLPOS**)
 - The uterus is next involved and cavity dilated



C/F:

- Age – 14 -16
- Periodic lower abdominal pain which may be continuous.
- Primary amenorrhoea
- Urinary symptoms

On examination

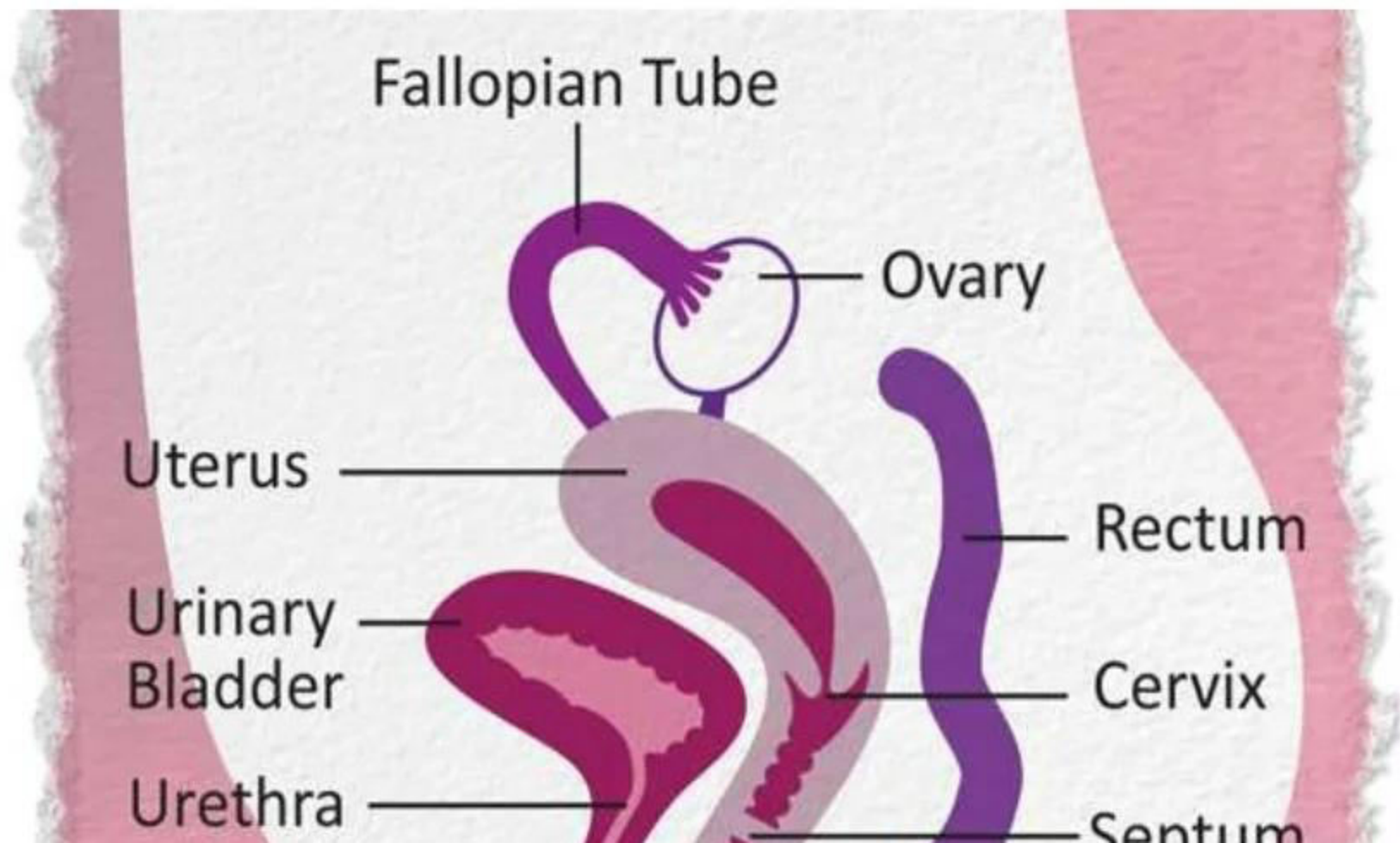
- Abdominal examination
 - Suprapubic swelling
- Vulval inspection:
 - Tense bulging membrane of bluish colouration
- Rectal examination:
 - Bulged vagina

Treatment

- Cruciate incision is made in the hymen.
- Quadrants of the hymen are partially excised not too close to the vaginal mucosa
- Spontaneous escape of dark tarry coloured blood is allowed.
- Patient should be made to lie down with the head end raised

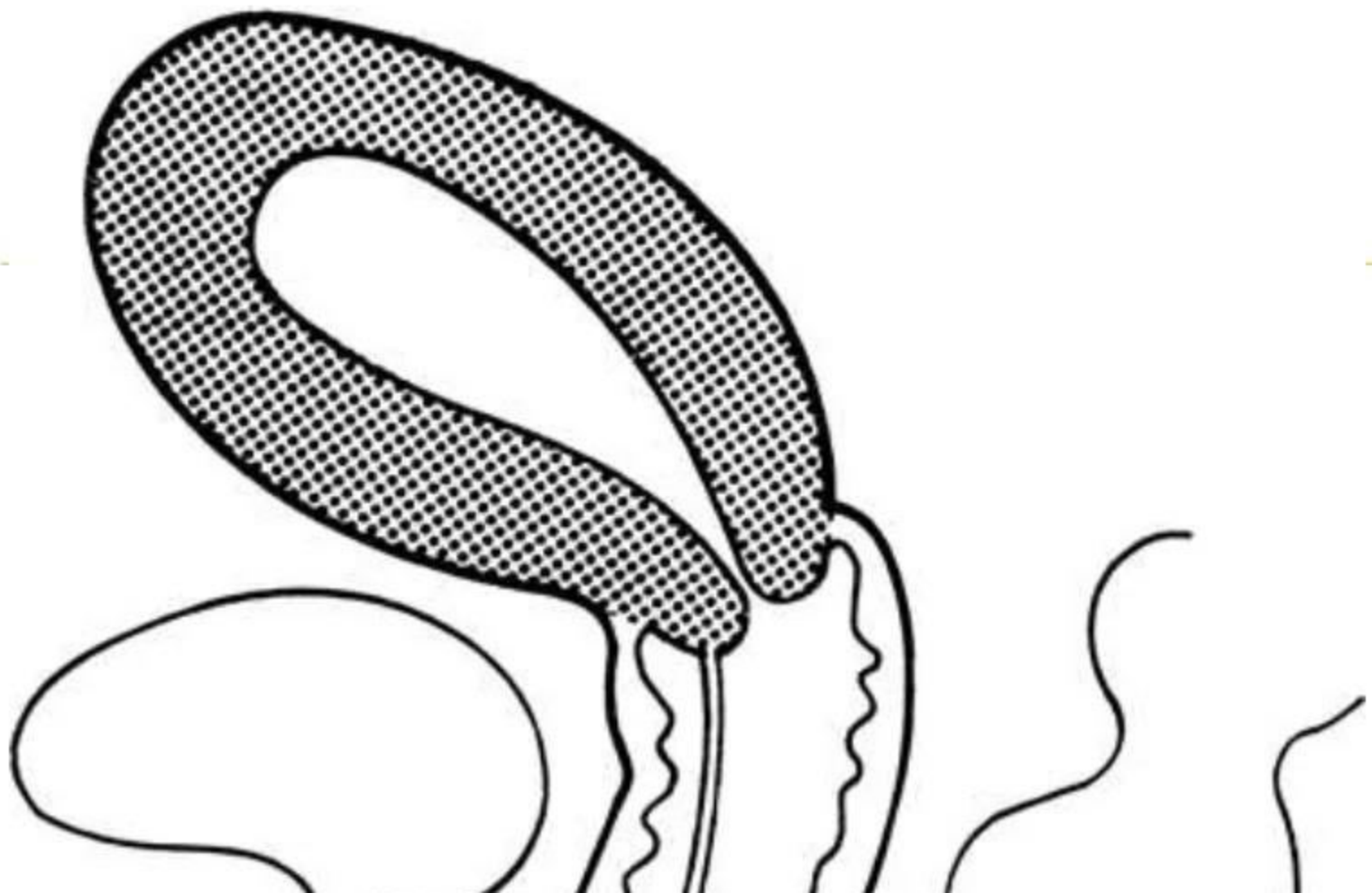TRANSVERSE SEPTUM ABOVE THE LOWER ONE – THIRD...

- Usually comes earlier than the previous one with the septum placed higher and higher
- Same presenting features, but urinary symptom absent.
- Same surgical treatment



SEPTATE VAGINA

- Complete or incomplete longitudinal septum
- May be assoc with double uterus and double cervix
- May be asymptomatic or may produce dyspareunia o may obstruct delivery
- Treatment: septum to be excised.



PARTIAL ATRESIA OF THE VAGINA

- A segment of the vagina may be atretic in the upper third. May be assoc with cervical atresia
- Functioning uterus (usually)
- Primary amenorrhoea, periodic pain in lower abdomen with a mass felt per abdomen or rectal examination point to the diagnosis.

Excision of the atretic portion from below and

COMPLETE ATRESIA

- Assoc with absence of uterus
- Healthy gonads and fallopian tubes
- Pt is phenotypically female with normal karyotype pattern
- Entity is often assoc with urinary tract abnormality
→ called Rokitansky – Kuster – Hauser syndrome

The background of the slide is a vibrant yellow color. On the left and right sides, there are vertical decorative borders. These borders consist of a dense, overlapping pattern of various international currency symbols, including the dollar sign (\$), the pound sterling (£), the euro (€), and the yen (¥). The symbols are rendered in a 3D, embossed style, giving them a textured appearance. In the center of the slide, the text "Uterine Anomalies..." is written in a large, bold, black, sans-serif font. Below the text, there is a thin, horizontal yellow line that spans across the width of the text.

Uterine Anomalies...

FAILURE OF FUSION OF MULLERIAN DUCTS

- In majority, the presence of deformity escapes attention.
- Detection is made accidentally during the investigation of infertility or repeated pregnancy wastage.
- In other cases, diagnosis is made during D + E operation , manual removal of placenta or during Caesarean section.

Uterine tube

Indentation

A

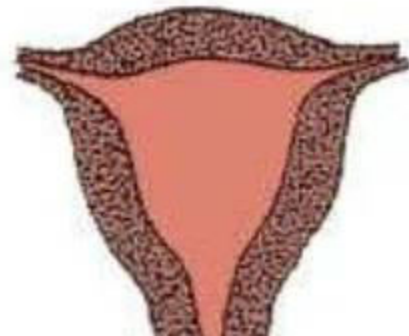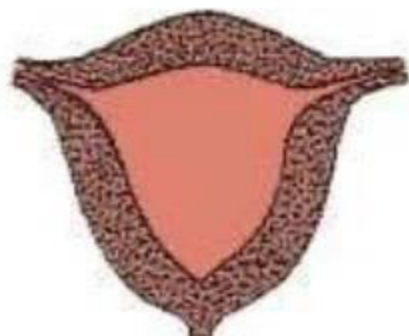
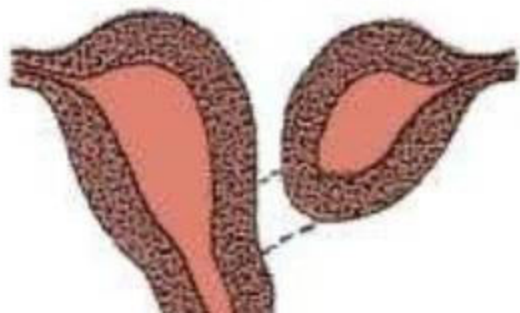
Uterus didelphys
with double vagina

B

Uterus arcuatus

C

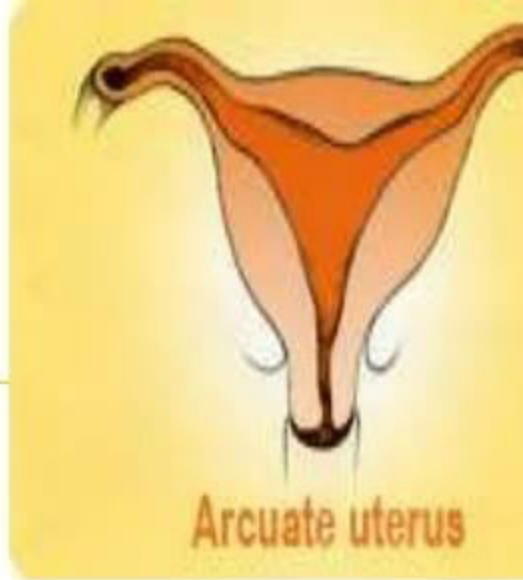
Uterus bicornis

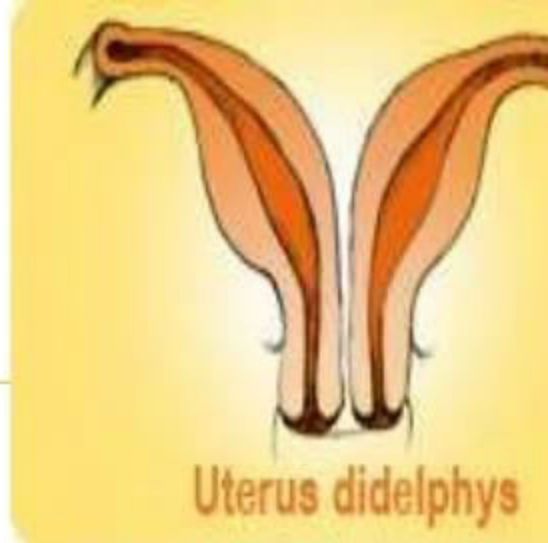


TYPES:

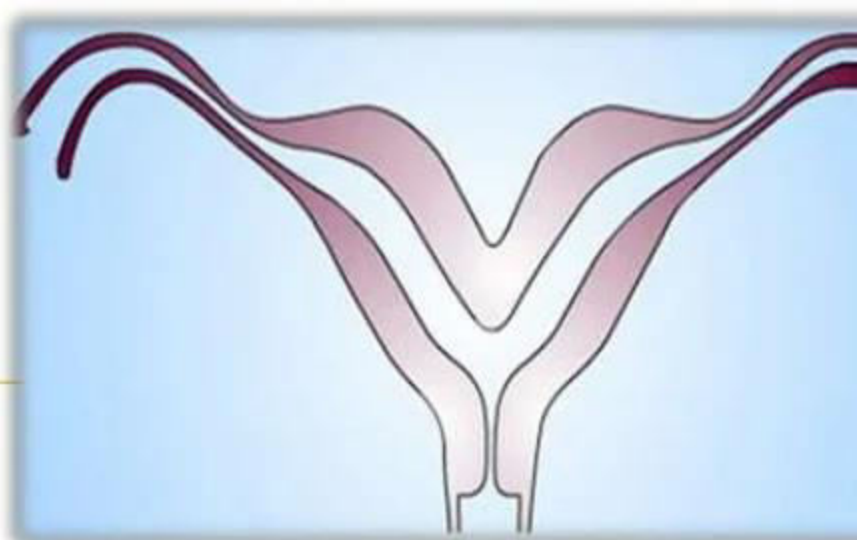
- **Arcuate**

- Fundus looks concave with heart shaped cavity outline
- This looks more like a normal uterus, except it has a dip, or slight indentation at the top.
- It is a common abnormality, affecting about one in 25 women in the general population.





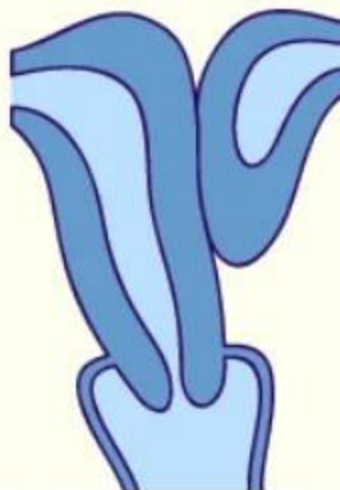
-
- Uterus didelphys
 - Complete lack of fusion of the Mullerian ducts with a double uterus and a double vagina.
 - This is when the uterus has two inner cavities.
 - Each cavity may lead to its own cervix and vagina, so there are two cervixes and two vaginas.
 - It is uncommon, affecting about one in 350 women.
 - It is possible to conceive if you have this type of abnormality



- Uterus bicornis

- There are varying degree of fusion of the muscle walls of the two ducts.
- Uterus bicornis bicollis : 2 uterine cavity with double cervix with or without vaginal septum.

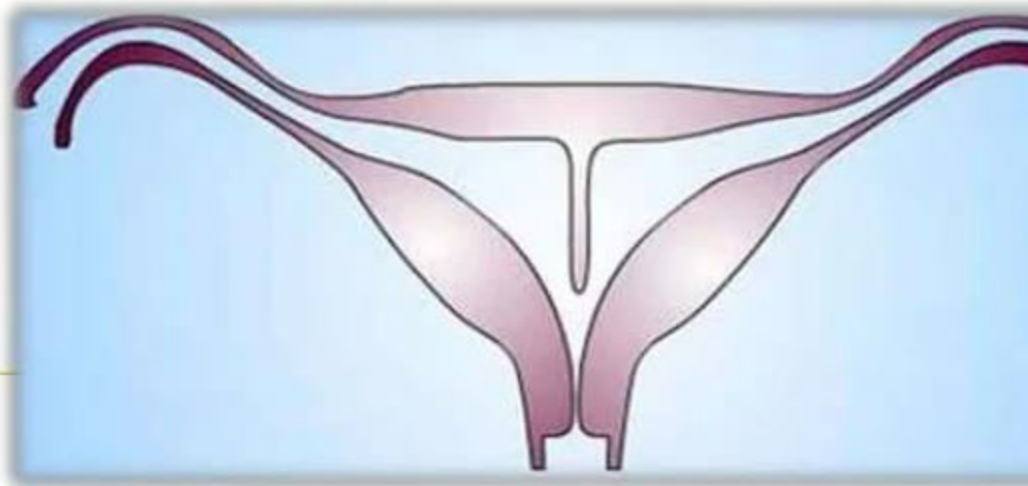




- Uterus bicornis unicollis

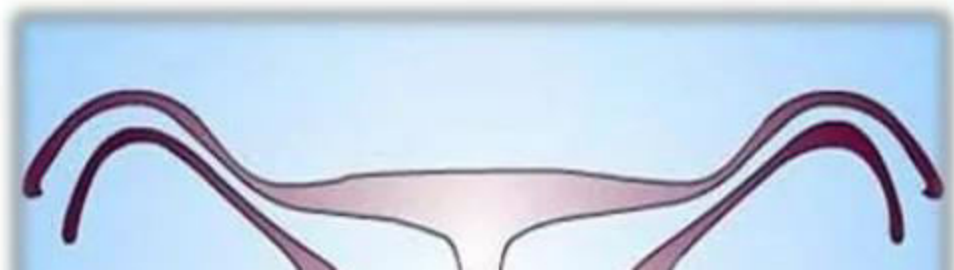- 2 uterine cavity with one cervix
- Horns may be equal or one horn may be rudimentary and have no communication with the developed horn.





- Septate uterus

- 2 mullerian ducts fused together but there is persistence of septum in between the two either partially or completely



Clinical Features

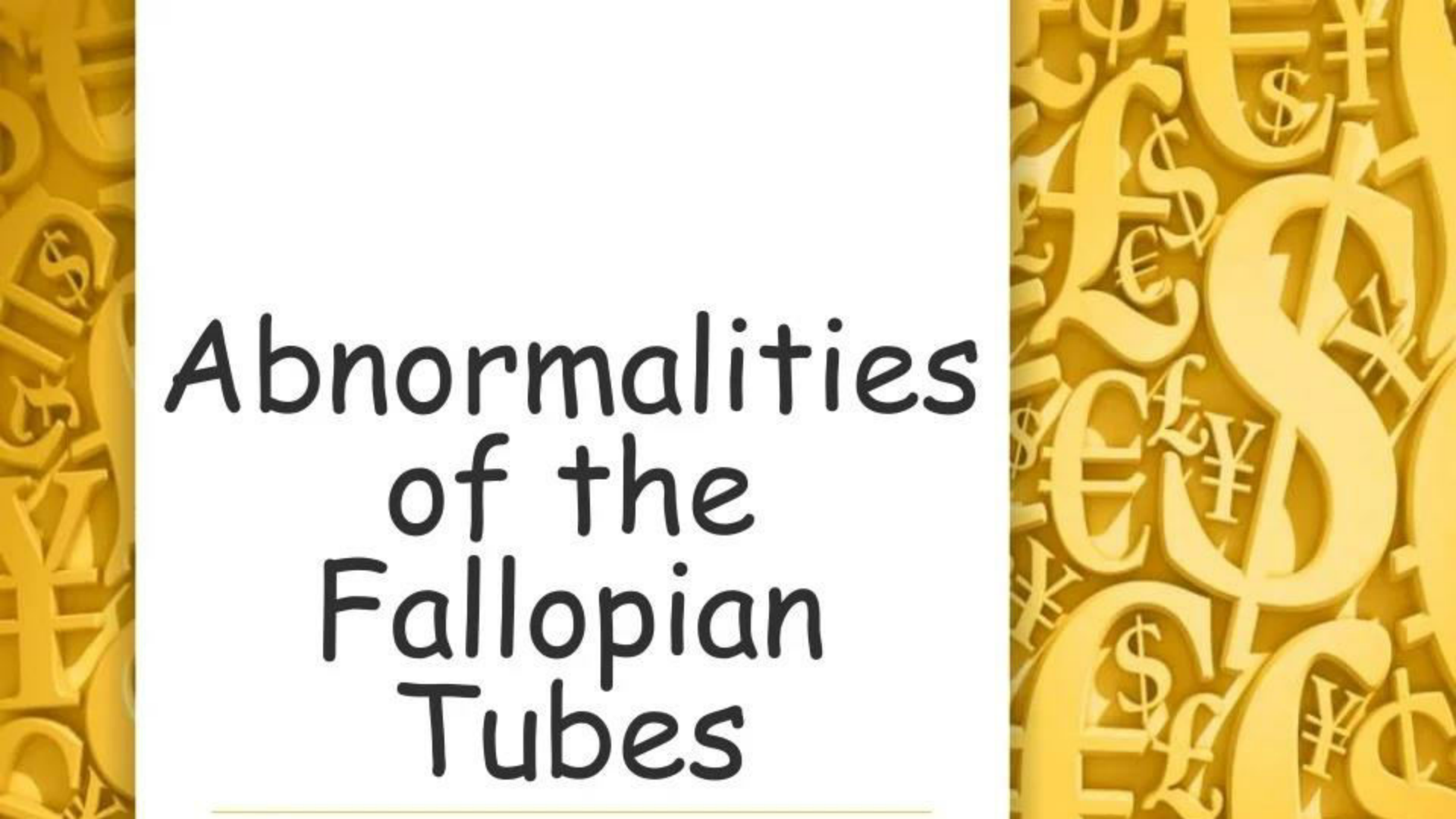
- May not produce any clinical manifestation.
- Gynaecological:
 - Infertility and dyspareunia often related – vaginal septum
 - Menorrhagia – due to increased surface area in bicornuate uterus

- Obstetrical


- Midtrimester abortion – may be recurrent
- Increased incidence of malpresentation – transverse lie in arcuate or septate, breech in bicornuate, unicornuate or complete or septate uterus
- Preterm labour
- Prolonged labour – due to incoordinate uterine action
- Obstructed labour

Treatment

- Rudimentary horn can be excised to prevent any obstetrical complications
- Uterine septum can be effectively resected hysteroscopically either by scissors or laser

The background of the slide is a golden-yellow color with a dense, repeating pattern of various international currency symbols, including the dollar sign (\$), Euro symbol (€), Pound sterling symbol (£), and Japanese Yen symbol (¥). The symbols are rendered in a 3D, embossed style, creating a textured effect.

Abnormalities of the Fallopian Tubes

- 
-
- Tubes may be unduly elongated
 - Rarely tube may be absent on one side
 - These may lower the fertility or favour ectopic pregnancy

The background of the slide is a golden-yellow color with a dense, repeating pattern of various international currency symbols, including the dollar sign (\$), pound sterling (£), euro (€), yen (¥), and Canadian dollar (C\$). The symbols are rendered in a 3D, embossed style, creating a textured effect. The central text is set against a plain white background.

Anomalies of the Ovaries

-
- There may be streak of gonads or gonadal dysgenesis which are usually associated with errors of sex chromosomal pattern.
 - No treatment will help this condition
 - Accessory ovary may be present
 - Supranumerary ovaries may be present in the broad ligament or elsewhere (rare)